



**PATIENT**

Hannah Carter

**SPECIES**

Canine

**BREED**

Border Collie

**SEX**

Female Spayed

**AGE**

10.3.10

**WEIGHT**

64lbs

**INTERPRETED BY**

Maggie Machen Lamy,  
DVM, DACVIM  
(Cardiology)

**HOSPITAL NAME**

Hickory Veterinary  
Hospital

**REFERRING VET**

Dr. Silcox

**INVOICE**

23908

**DATE**

4.26.22

**PRESENTING CLINICAL SIGNS**

History: Recheck echo. Patient has a history of a heart murmur (grade 2/6).

-Pertinent abnormal PE/Chem/CBC/UA Results: See attached.

-Current medications: Incurin 1mg SID, Enalapril 10mg SID, heartworm preventative Sentinel.

-Sedation used: Not required to complete full diagnostic ultrasound.

-Pertinent previous ultrasound results (5/2021 MML): Mild MR, mild LAE, mild LVE, trace TR. LA: 2.9, LV: 4.4

-STAT: Not requested

-Imaging performed by: Andi Parkinson, RDMS.

**ECHOCARDIOGRAM FINDINGS**

2D, m-mode, color flow and doppler imaging is available. Diffuse thickening of mitral valve leaflets (anterior>posterior) with no prolapse into the left atrial lumen. Moderate eccentric mitral regurgitation with moderate left atrial dilation. Normal MR velocity. Mildly increased LV diameter with hyperdynamic myocardial function. The tricuspid valve appears subjectively normal, with trivial tricuspid regurgitation. Normal right atrial and ventricular diameter. The pulmonic and aortic valves are normal in morphology and mobility. Normal pulmonic and aortic outflow velocities. No aortic or pulmonic insufficiency. No pericardial or pleural effusion noted. No cardiac tumors observed.

**CARDIAC CHART**

CANINE CARDIAC PARAMETERS	MR VMAX (m/s)	TR VMAX (m/s)	LA/AO (Boon method)	LA/AO (Heart Base; Swe)	FS (%)	EF (%)	EPSS (cm)
NORMAL PARAMETER	4.5-5.5	<2.7	1.3	<1.6	28-40	40-100	<0.6
PATIENT	5.3	NA	NM	1.8	30	56	NM
CANINE CARDIAC PARAMETERS	HR (BPM)	AV VMAX (m/s)	PV MAX (m/s)	BODY WEIGHT (kg)	LA 2D short axis Base view (cm)	LVIDd Avg; 2D and m-mode short axis (cm)	LVIDs Avg; 2D and m-mode short axis (cm)
NORMAL PARAMETER	50-100	0.7-1.7	0.7-1.6	BELOW	BELOW	BELOW	BELOW
PATIENT	145	1.2	1.2	29.0	3.6	5.0	3.6
*Normal chamber parameters expressed as a mean value (SD)				3	1.27 (5.3)	2.46 (2.46)	1.36 (5.5)
<b>BODY WEIGHT DEPENDENT PARAMETERS</b>				5	1.40 (4.5)	2.74 (5.2)	1.60 (4.7)
<i>*Note: All measurements based upon multi-modal images and methods. An average value is reported.</i>				10	1.50 (3.8)	3.27 (3.5)	2.06 (3.1)
				15	1.83 (2.0)	3.71 (2.4)	2.43 (2.1)
				20	2.02 (1.9)	4.14 (2.2)	2.80 (2.0)
				25	2.18 (2.4)	4.48 (2.9)	3.10 (2.5)
				30	2.33 (3.3)	4.83 (3.9)	3.39 (3.4)
				35	2.48 (4.3)	5.17 (5.0)	3.69 (4.5)
				40	2.62 (5.2)	5.48 (6.1)	3.96 (5.4)
				50	2.88 (7.1)	6.07 (8.3)	4.46 (7.4)

Adapted from June Boon, Veterinary Echocardiography, 1998  
Rishniw M and Hollis NE, J Vet Intern Med 2000; 14:429-435  
Hansson et al, Vet Rad and Ultrasound 2002  
Bonagura et al. Echocardiography: principles of interpretation, Vet Clin North Am 15:1177, 1995

## INTERPRETATION OF THE FINDINGS & FURTHER RECOMMENDATIONS

Chronic degenerative valve disease persists with evidence of progression. Previously mild disease has become moderate. Moderate mitral and trace tricuspid regurgitation are noted. Moderate left atrial enlargement indicates there is relatively low risk for imminent complication, however risk for progression to spontaneous congestive heart failure in the future is elevated. No additional issues are identified.

Given the risk for progression and results of the EPIC trial, Pimobendan is indicated in this patient as below. Assessment of progression in the future will help predict long term outcome, however prognosis is guarded at this stage (B2).

Omega fatty acid supplementation and mild salt restriction may also be of some long-term benefit. Monitor for development of a progressive cough, labored breathing, exercise intolerance or collapse episodes.

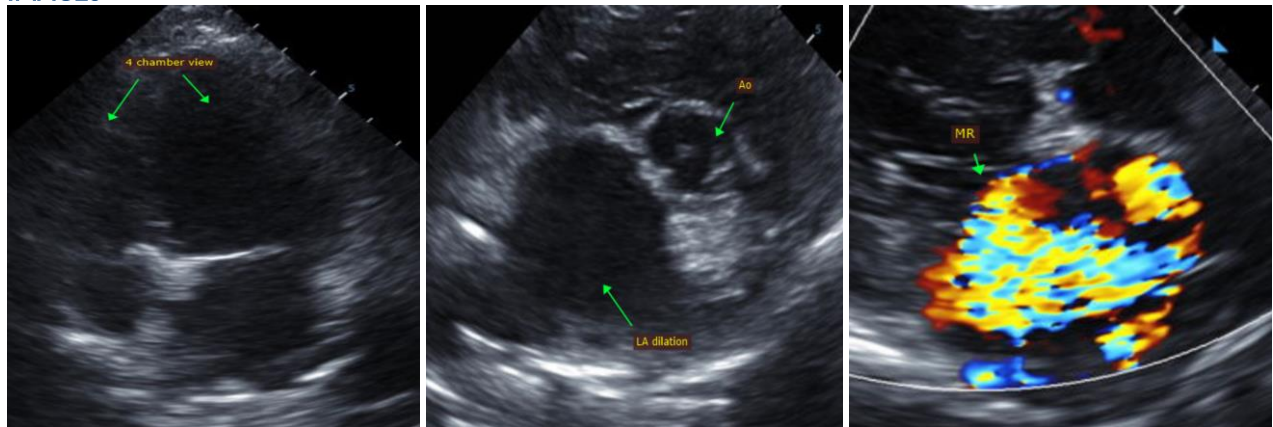
Once on the medication for 3-5 days, anesthetic risk is considered mildly elevated. Cardiac protective drug choices (opioid/benzodiazepine premedication, Propofol or alfaxalone induction, iso or sevo gas) are recommended. Monitor for arrhythmias, hypotension, and hypoxia both intra and post-operatively and intervene as necessary. Judicious IV fluid rates are recommended to avoid fluid overload. Avoid heart rate stimulating drugs such as atropine unless clinically indicated.

## PLAN

Baseline BP recommended. Institute heart muscle support Pimobendan 0.25-0.3mg/kg PO q12h.

Recommend monitor for progression with a recheck echocardiogram in 6 months, sooner if any development of clinical signs.

## IMAGES



**The information and recommendations provided are based on the images presented by the referring veterinarian. No evaluation can be communicated regarding pathology that was not visible in the image/video clips provided.**

Thank you for this referral. This report was generated using transcription software, and minor dictation errors may be present. If the clinical or image interpretation does not parallel your findings or if I can be of any further assistance, please contact me.

**Maggie Machen Lamy, DVM**  
**Diplomate of the American College of Veterinary Internal Medicine (Cardiology)**  
**info@sonopath.com**